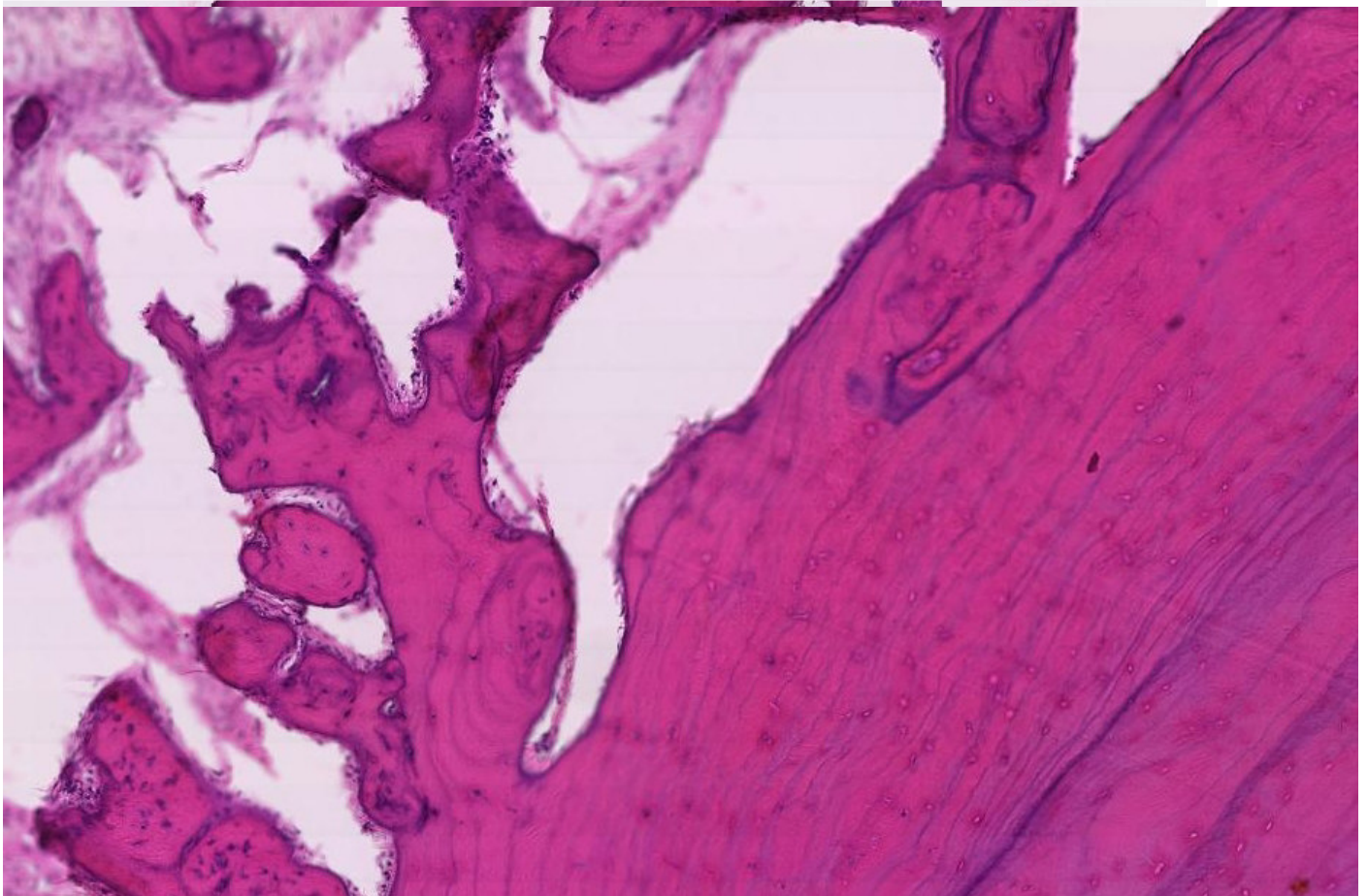
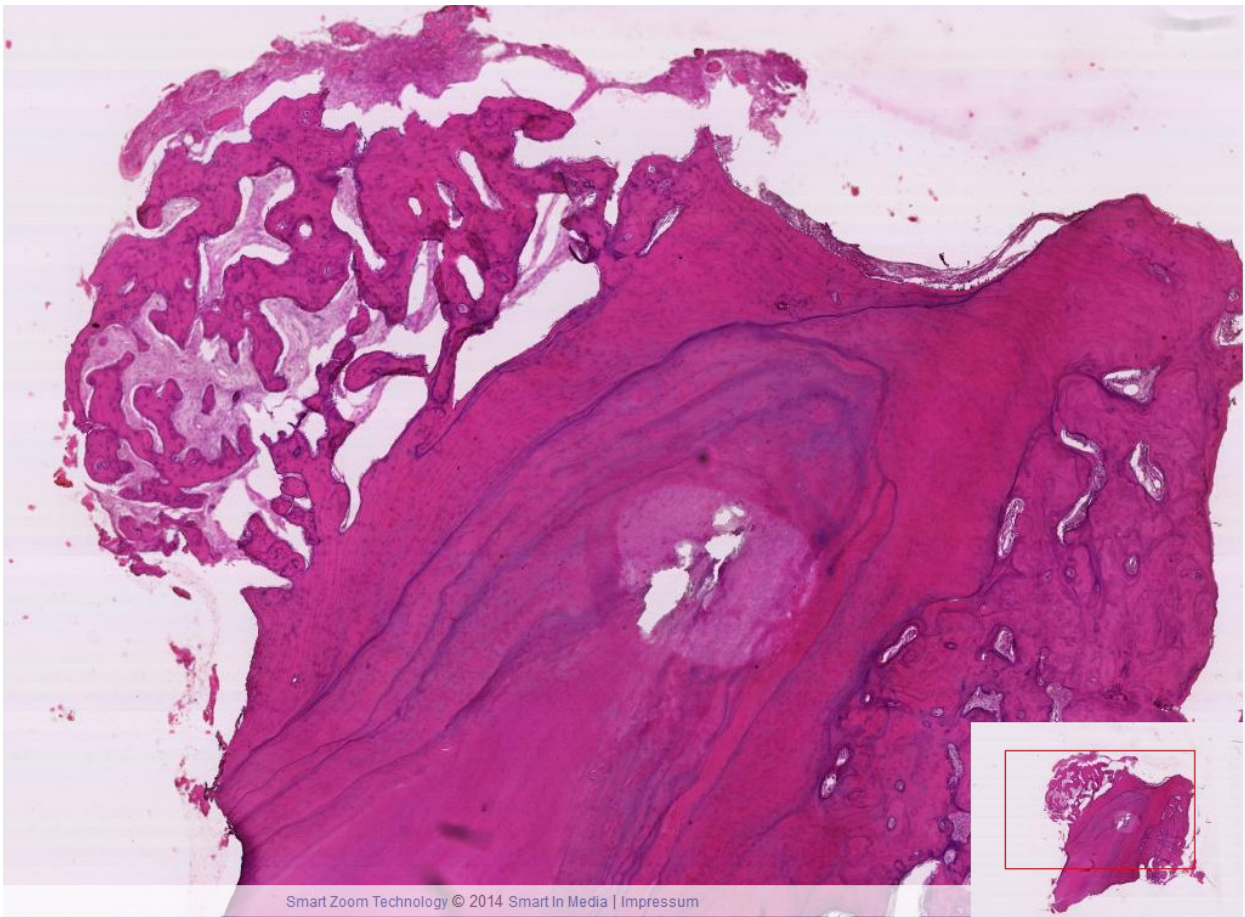
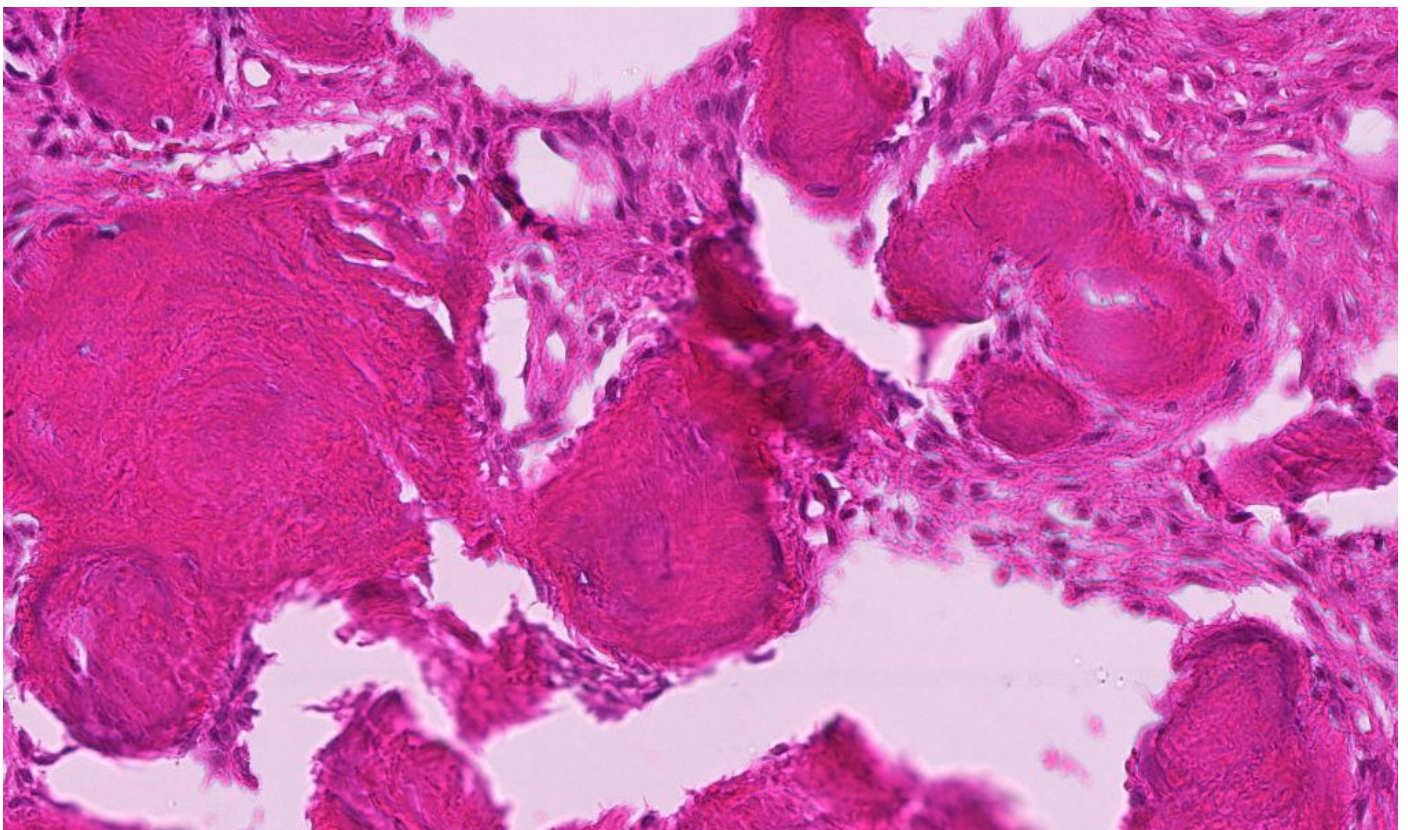
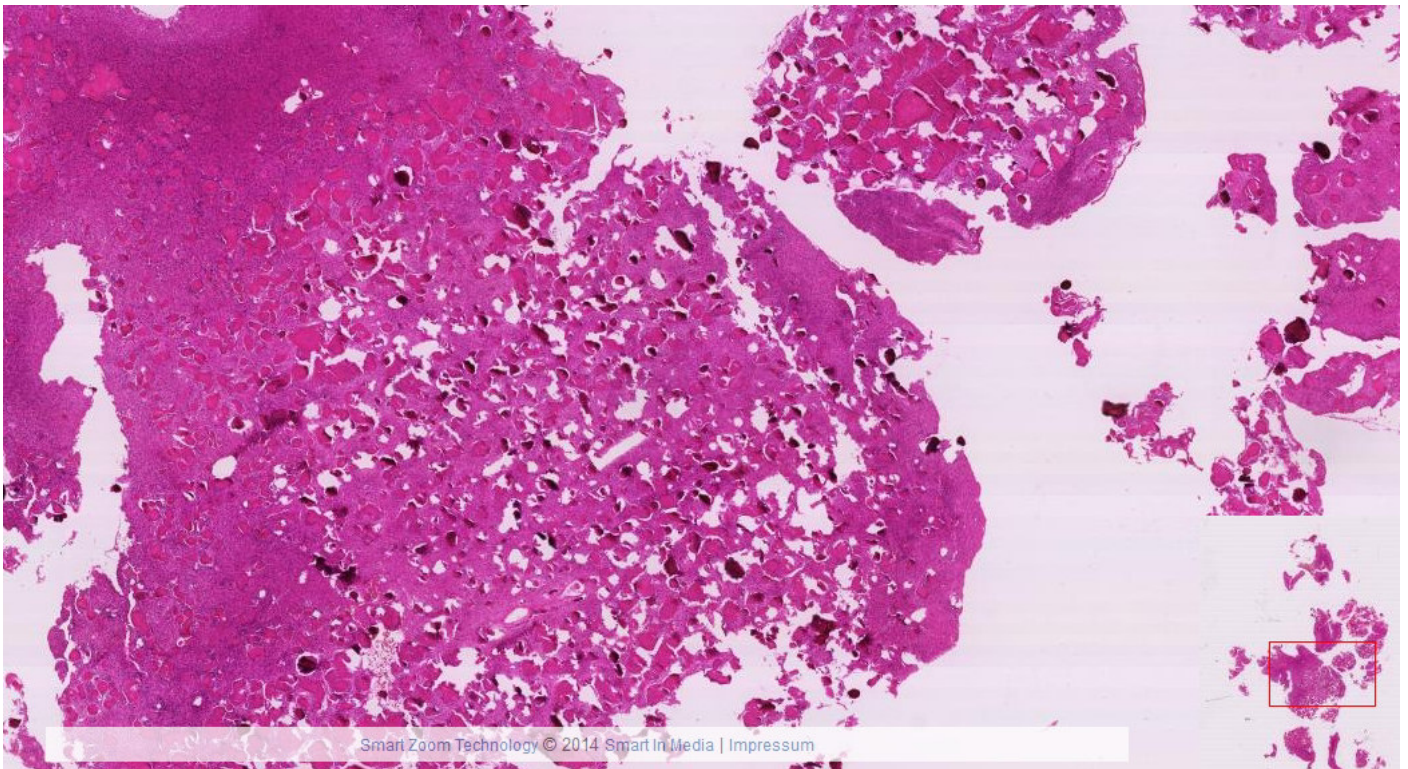


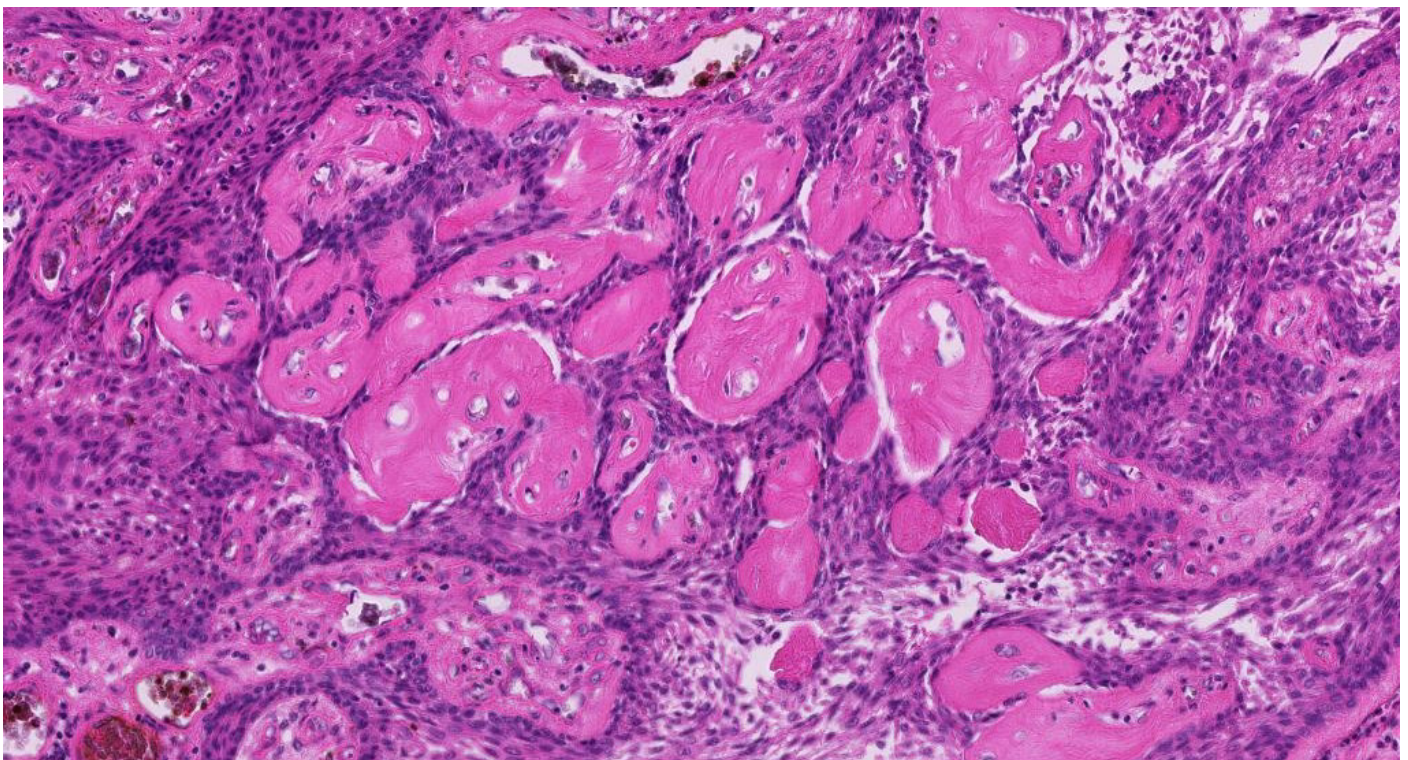
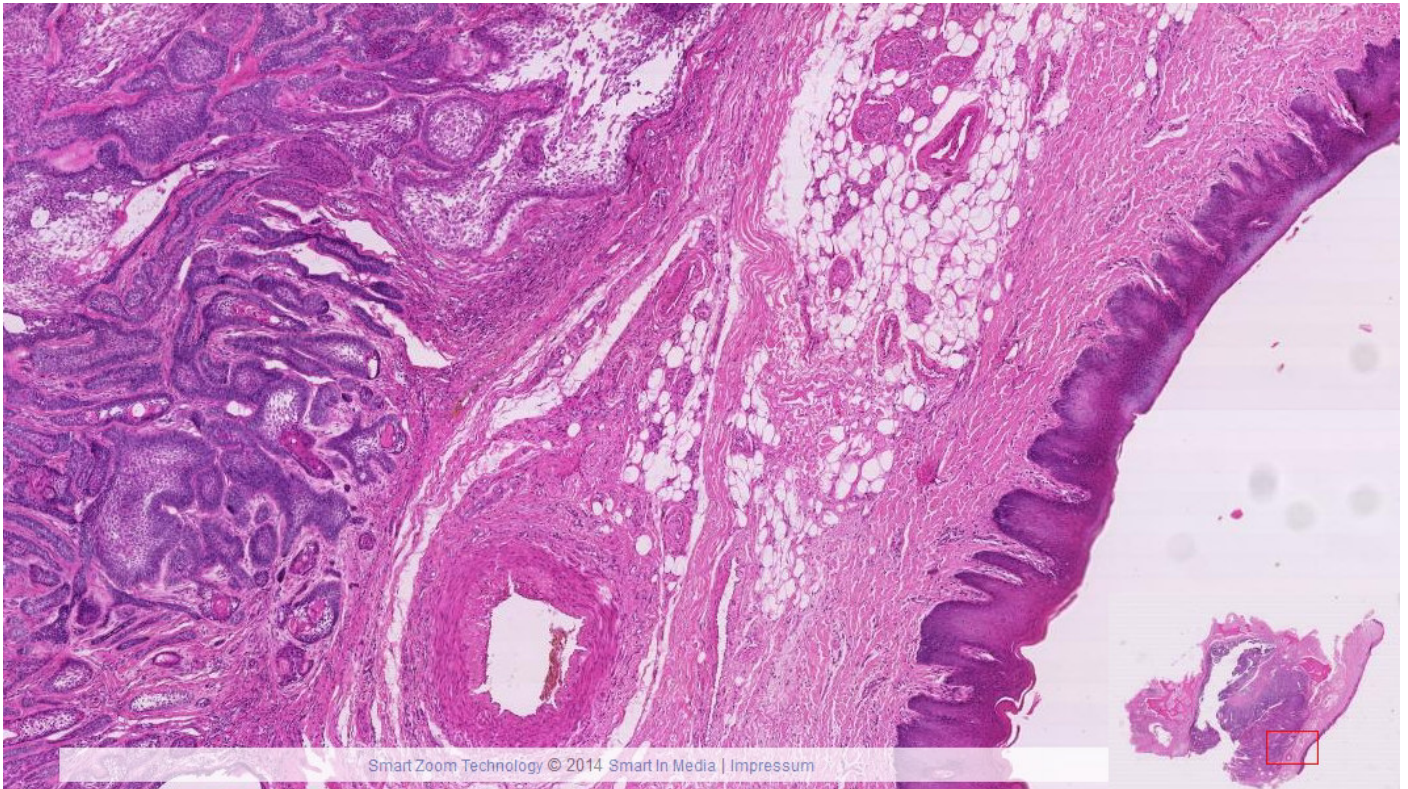
IX-1 Zementom (Zahn)



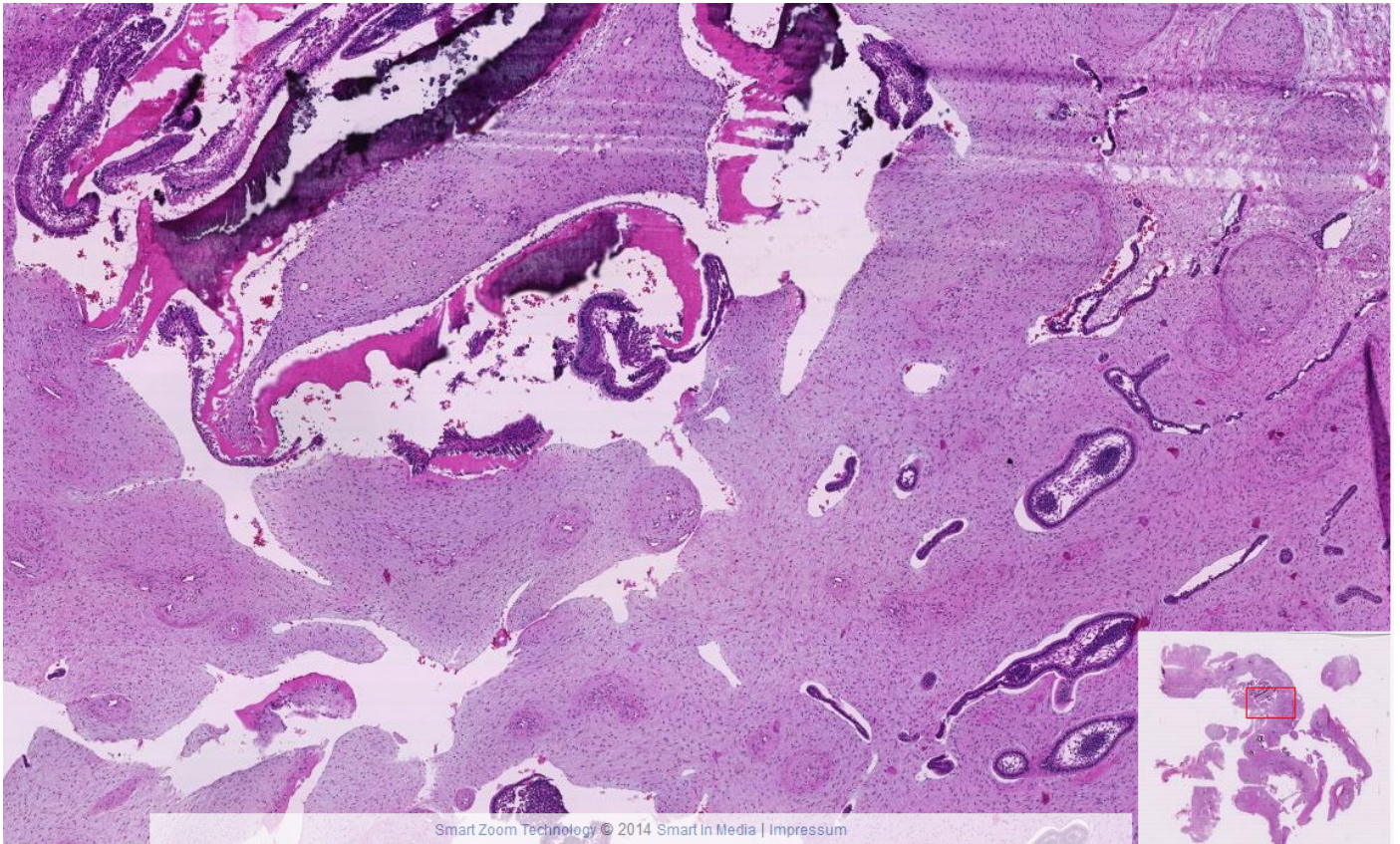
IX-2 Zementbildendes Fibrom (Kiefer)

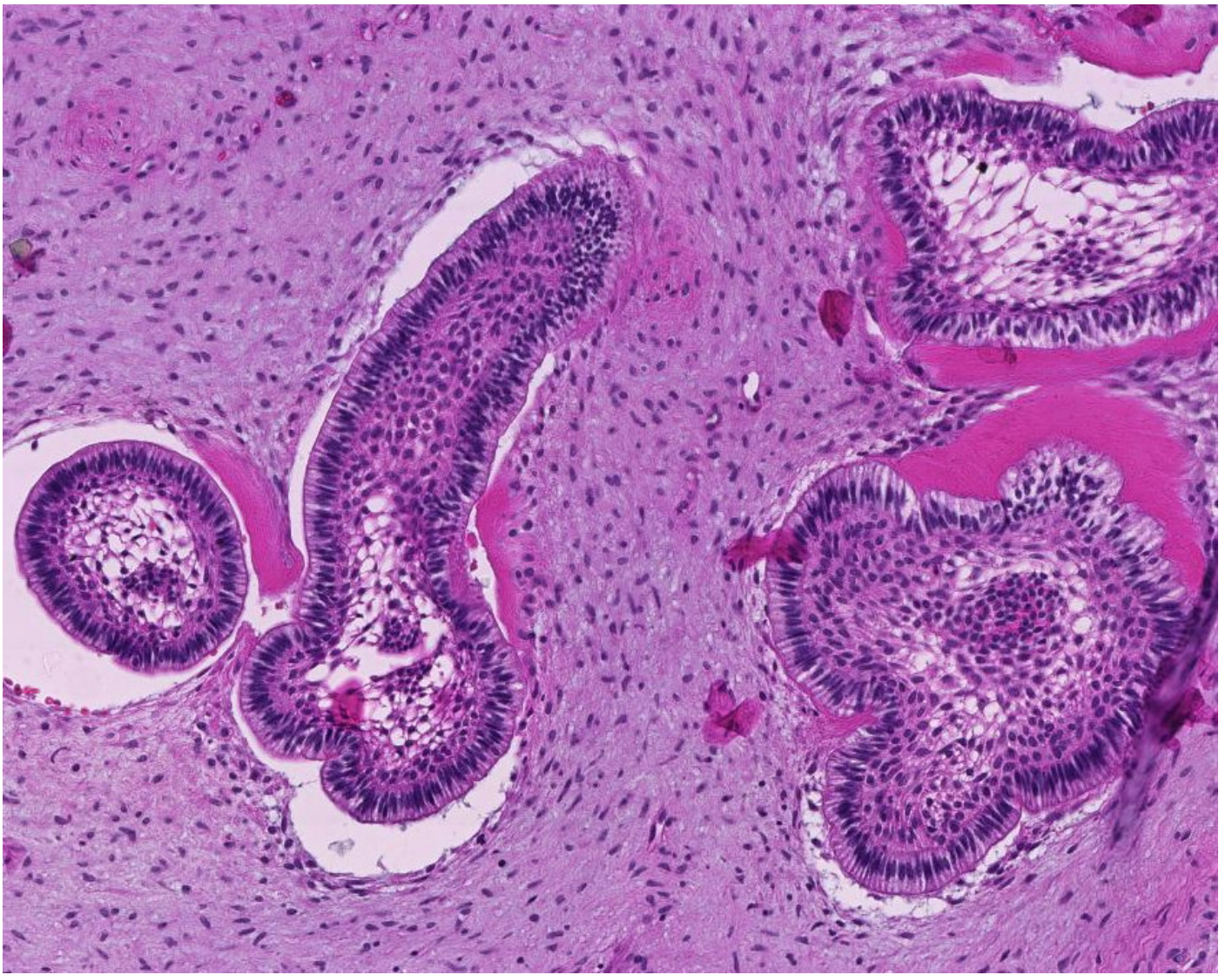


IX-3 Ameloblastom (Kiefer)

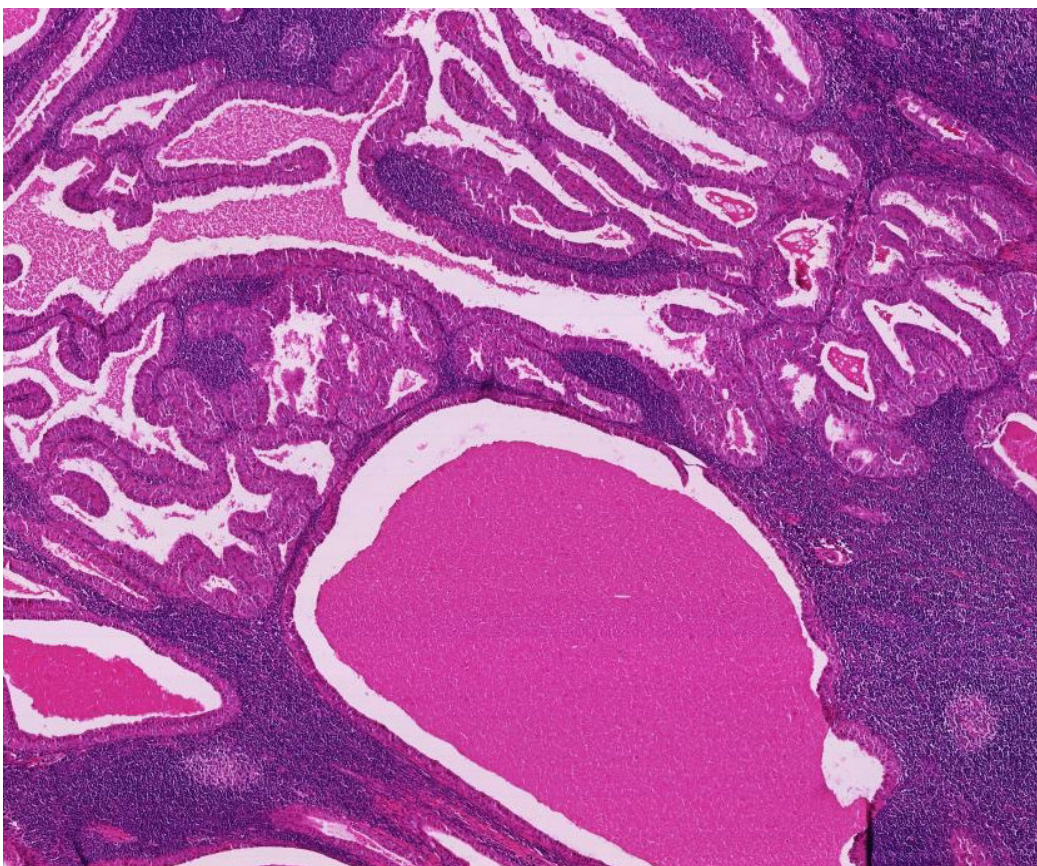
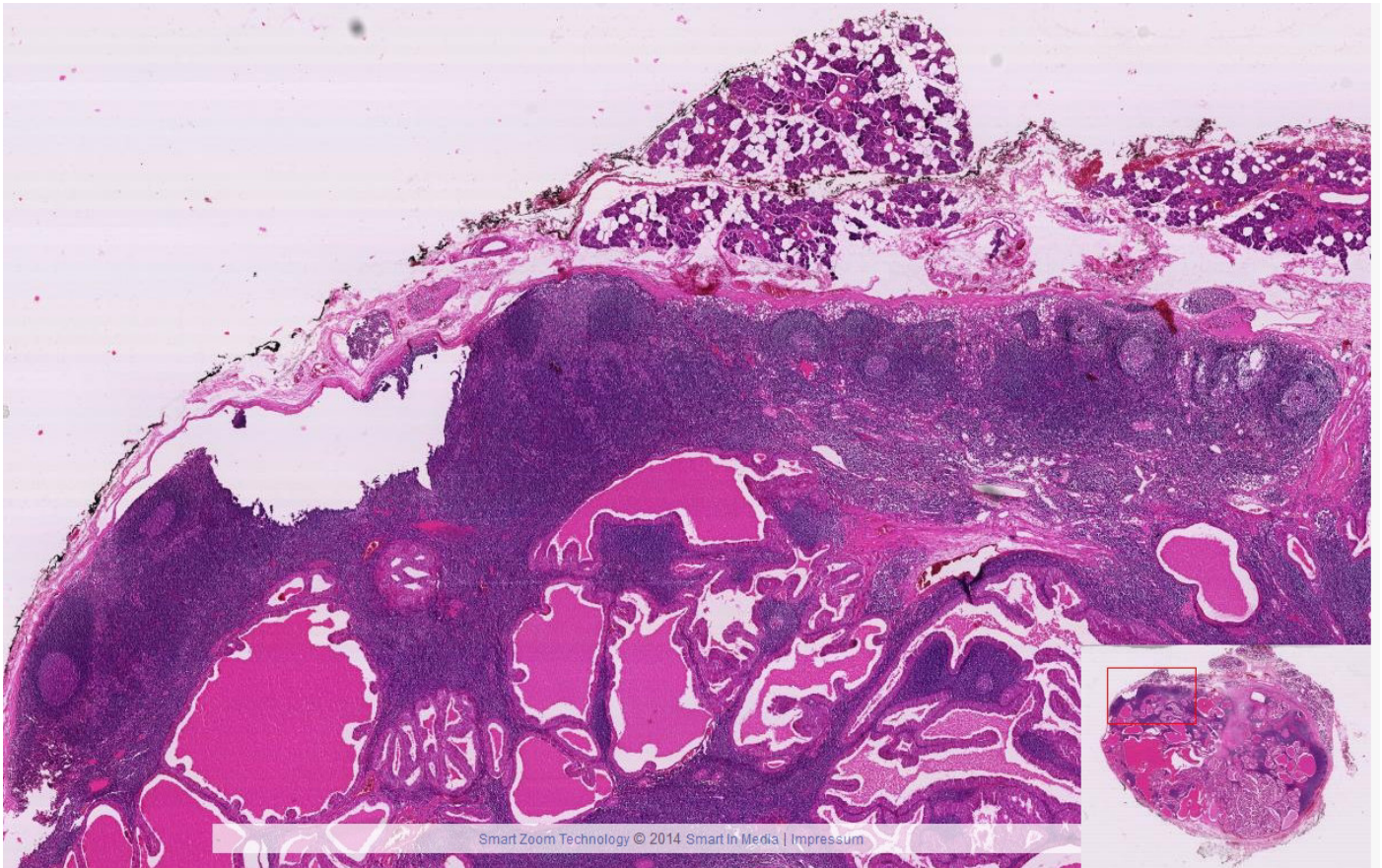


IX-4 Ameloblastotisches Fibroodontom(Kiefer)

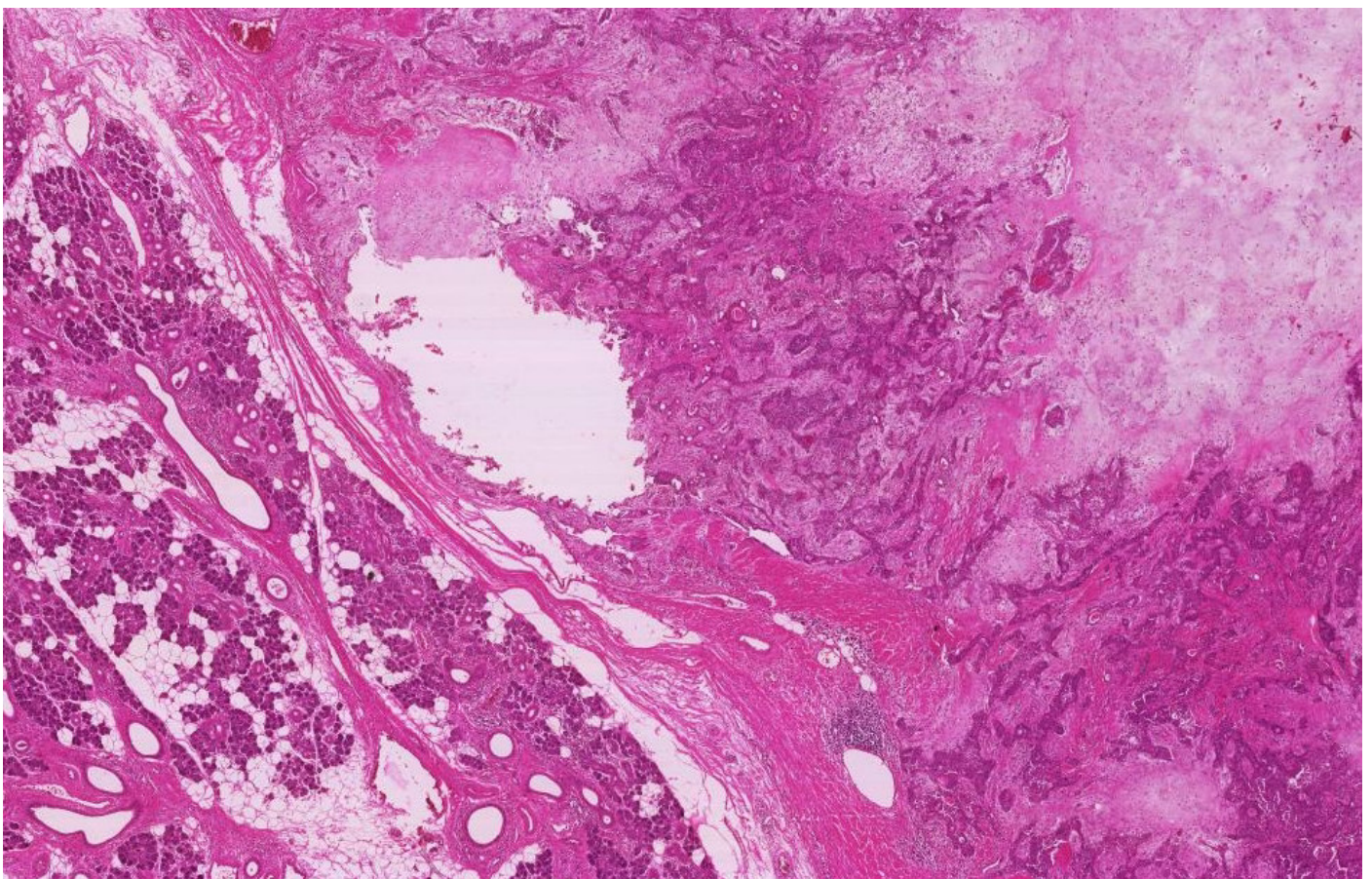
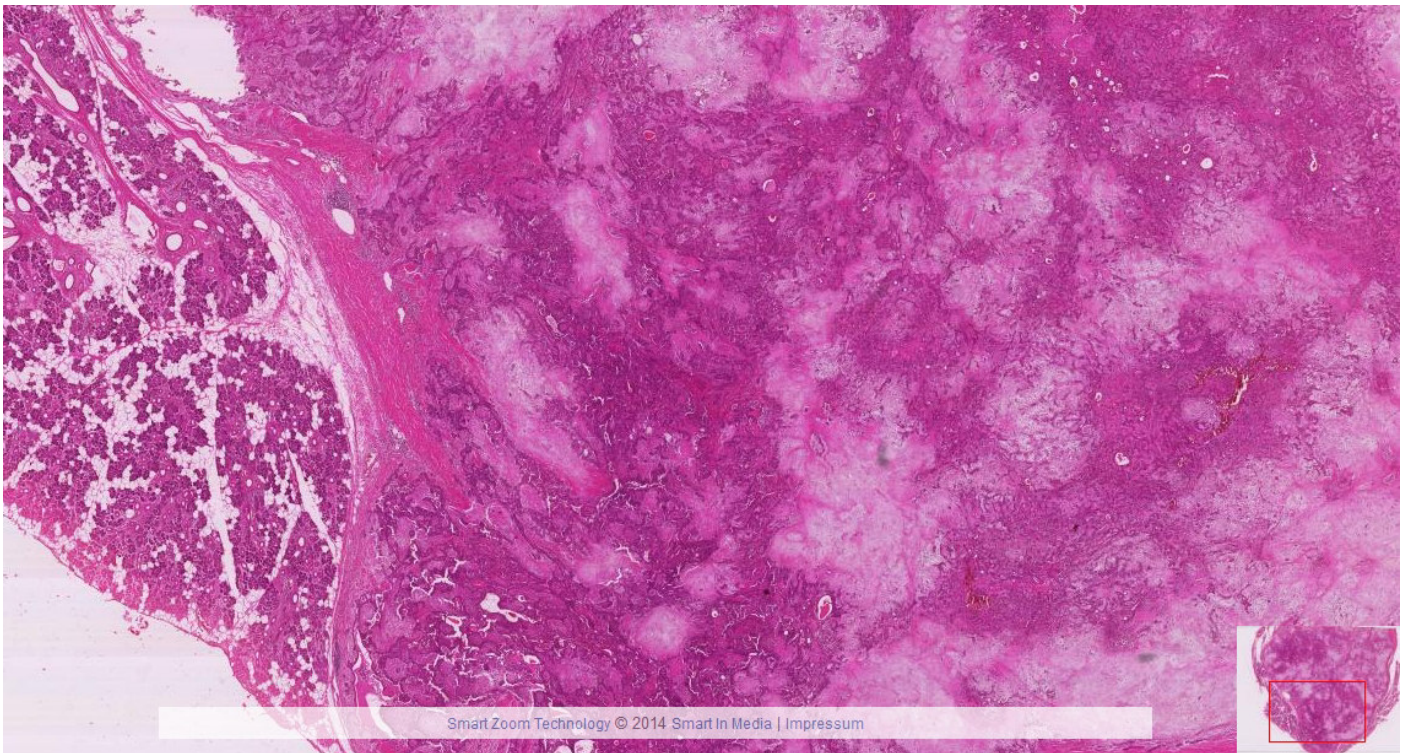


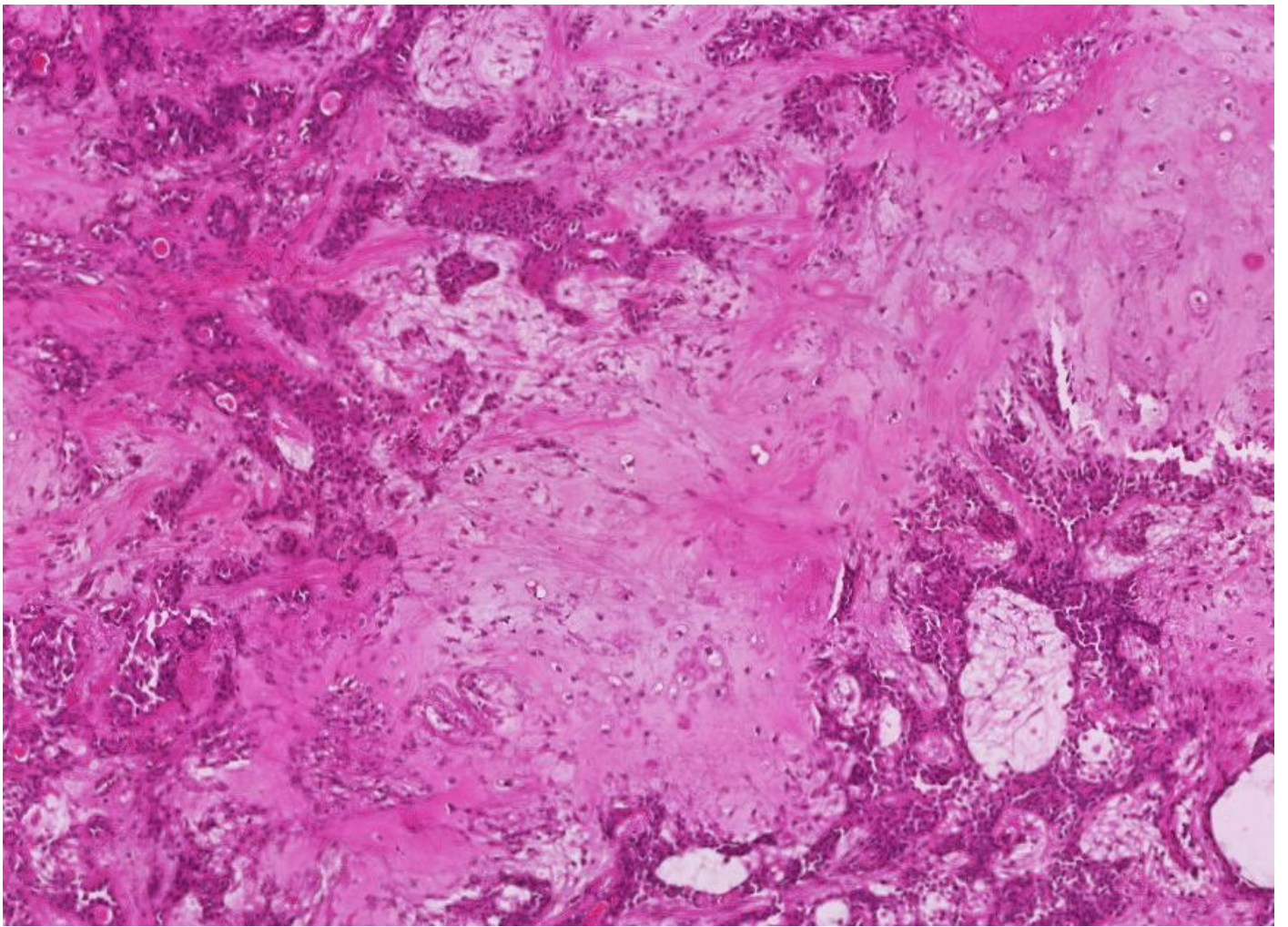


IX-5 (zyst-) Adenolymphom(Gl. Parotis)



IX -6 Pleomorphes Adenom (Gl. Parotis)





IX -7 Adenoid-zystisches Karzinom (kl. Speicheldrüse)

