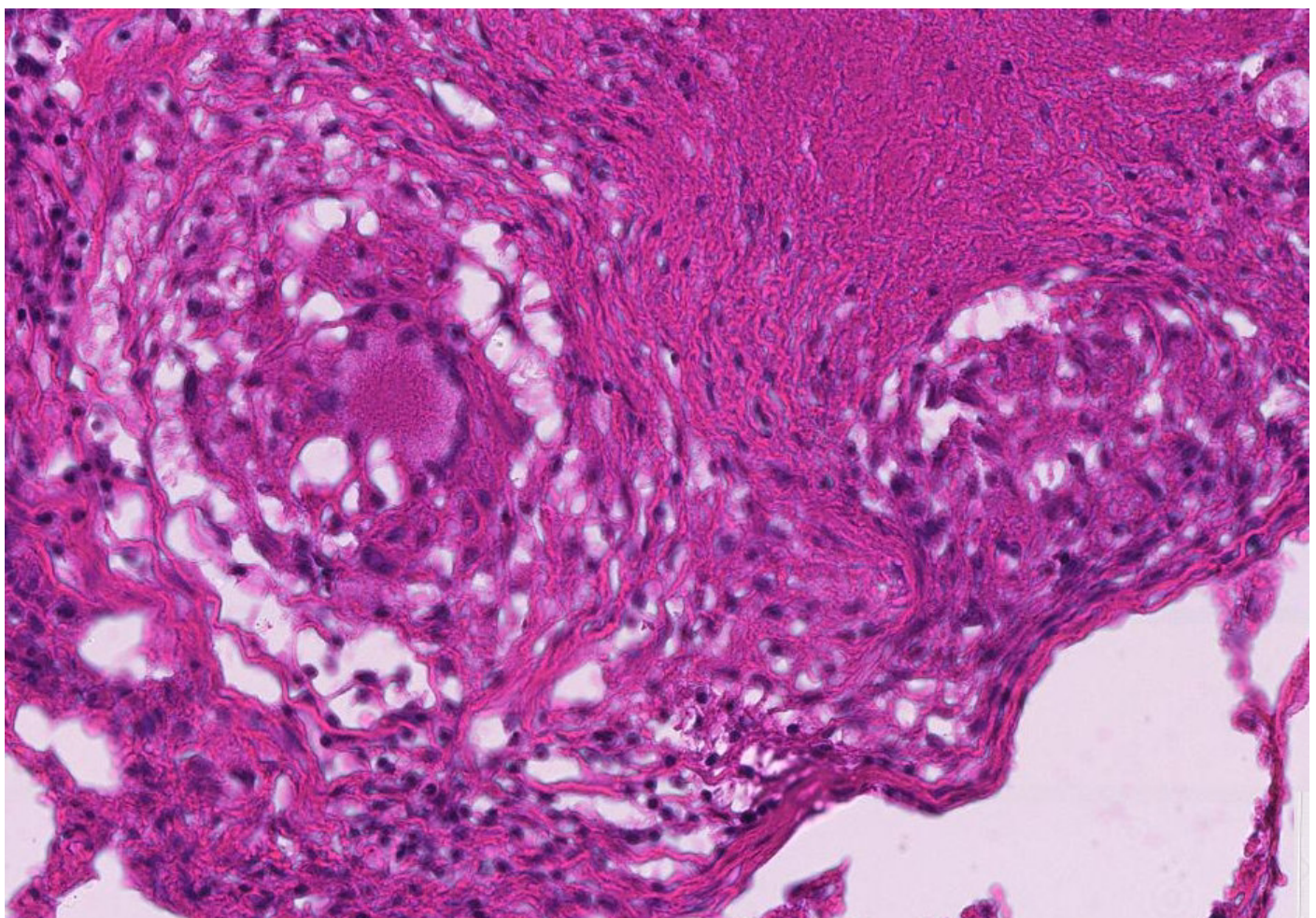
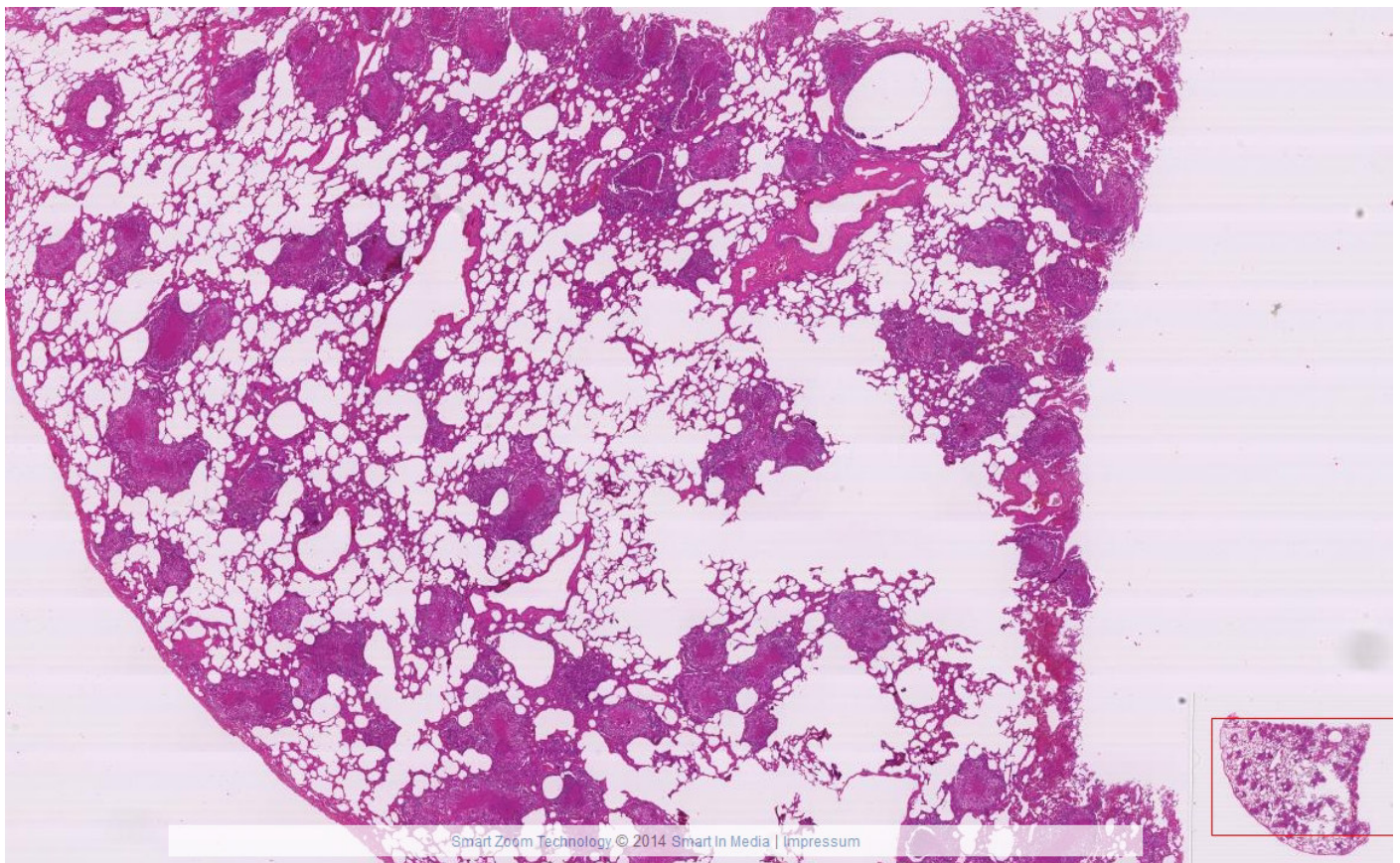
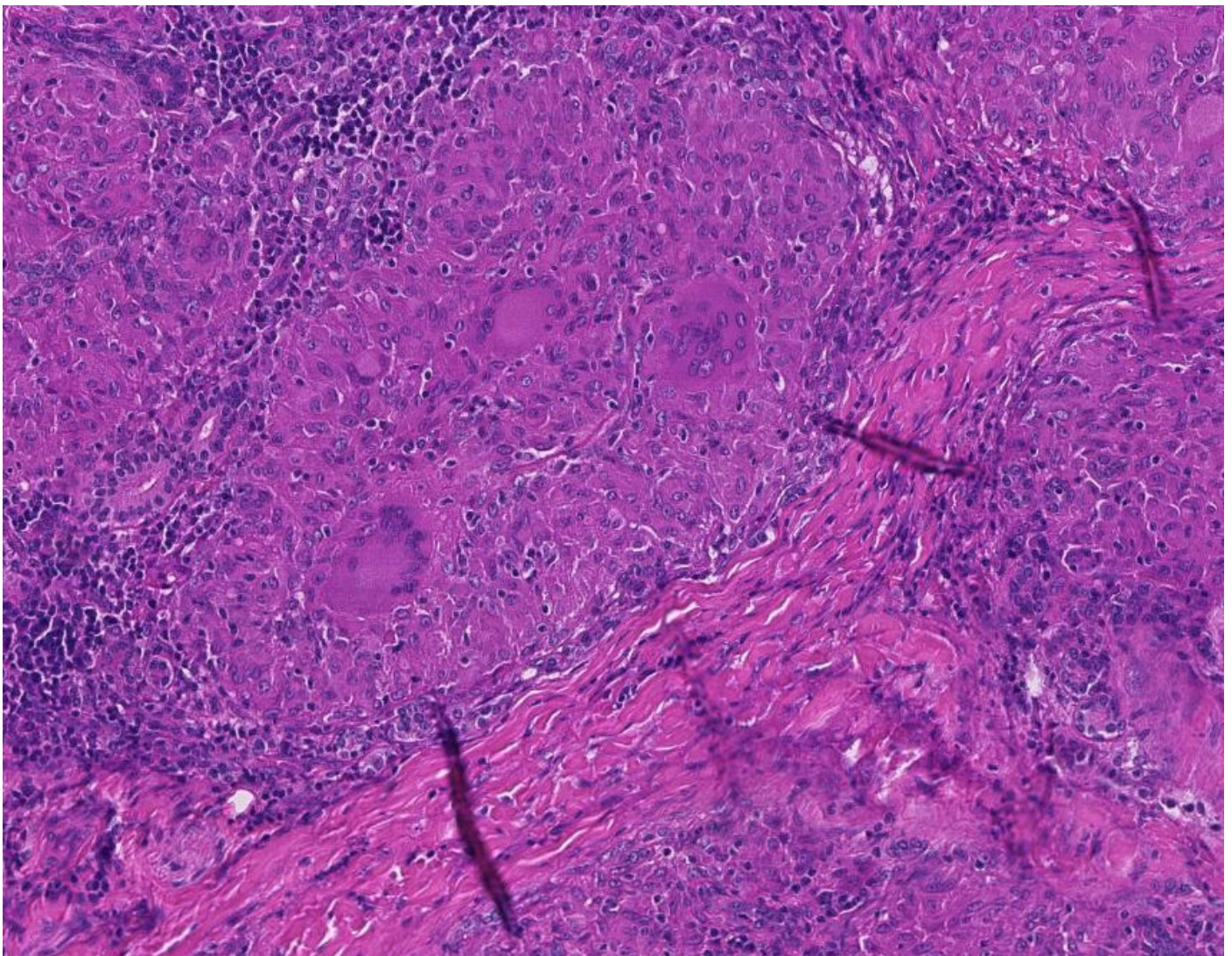
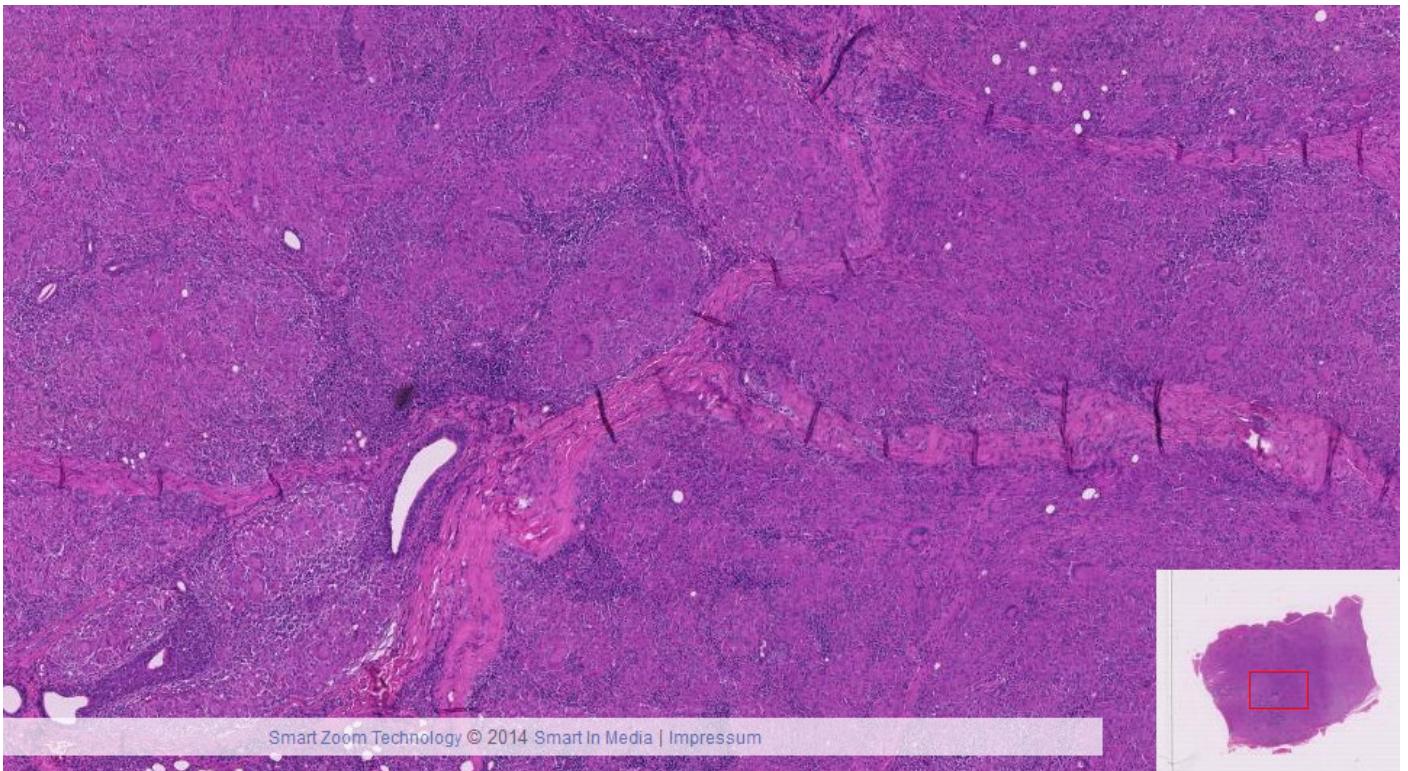


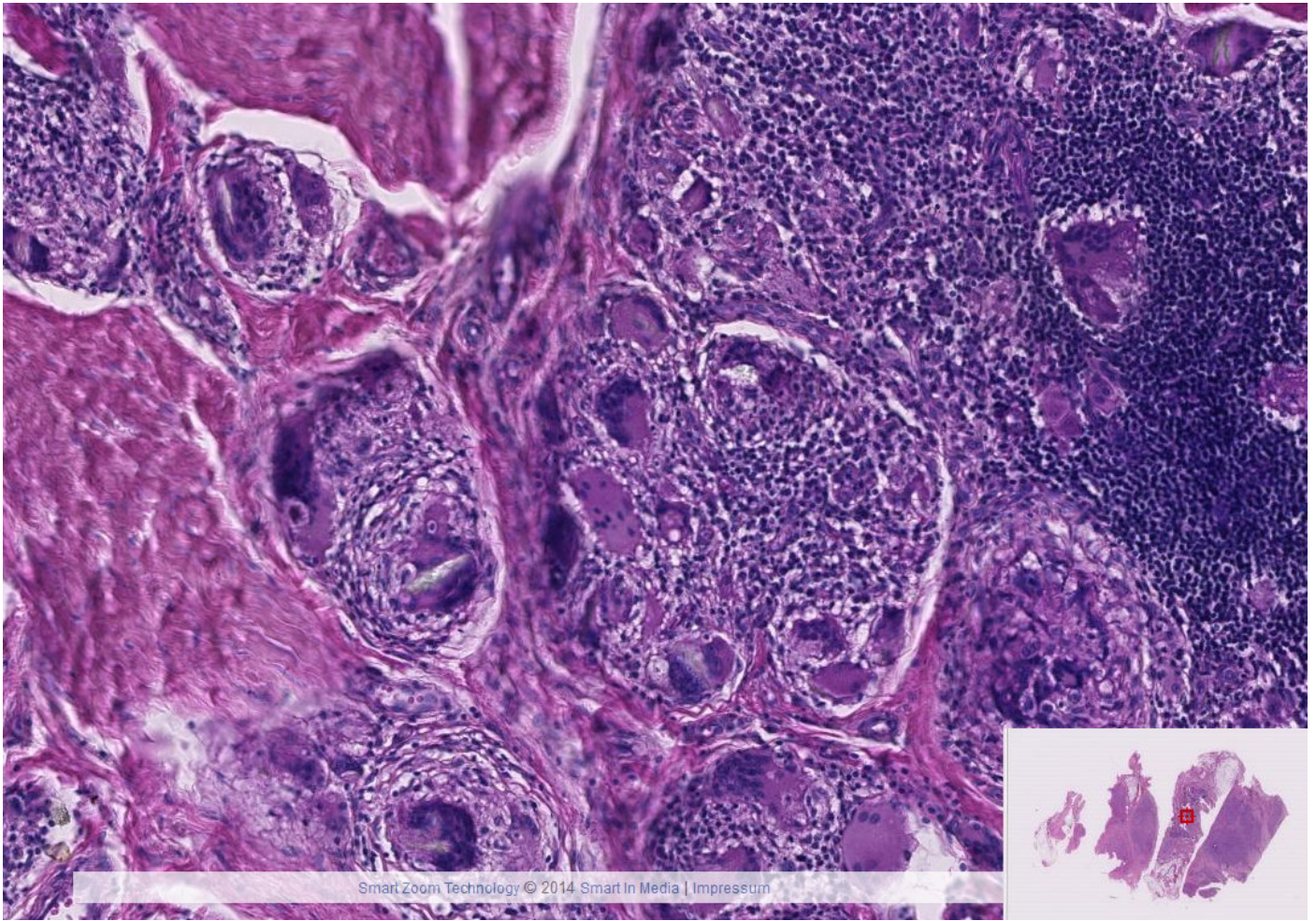
V-1 Miliartuberkulose (Lunge)



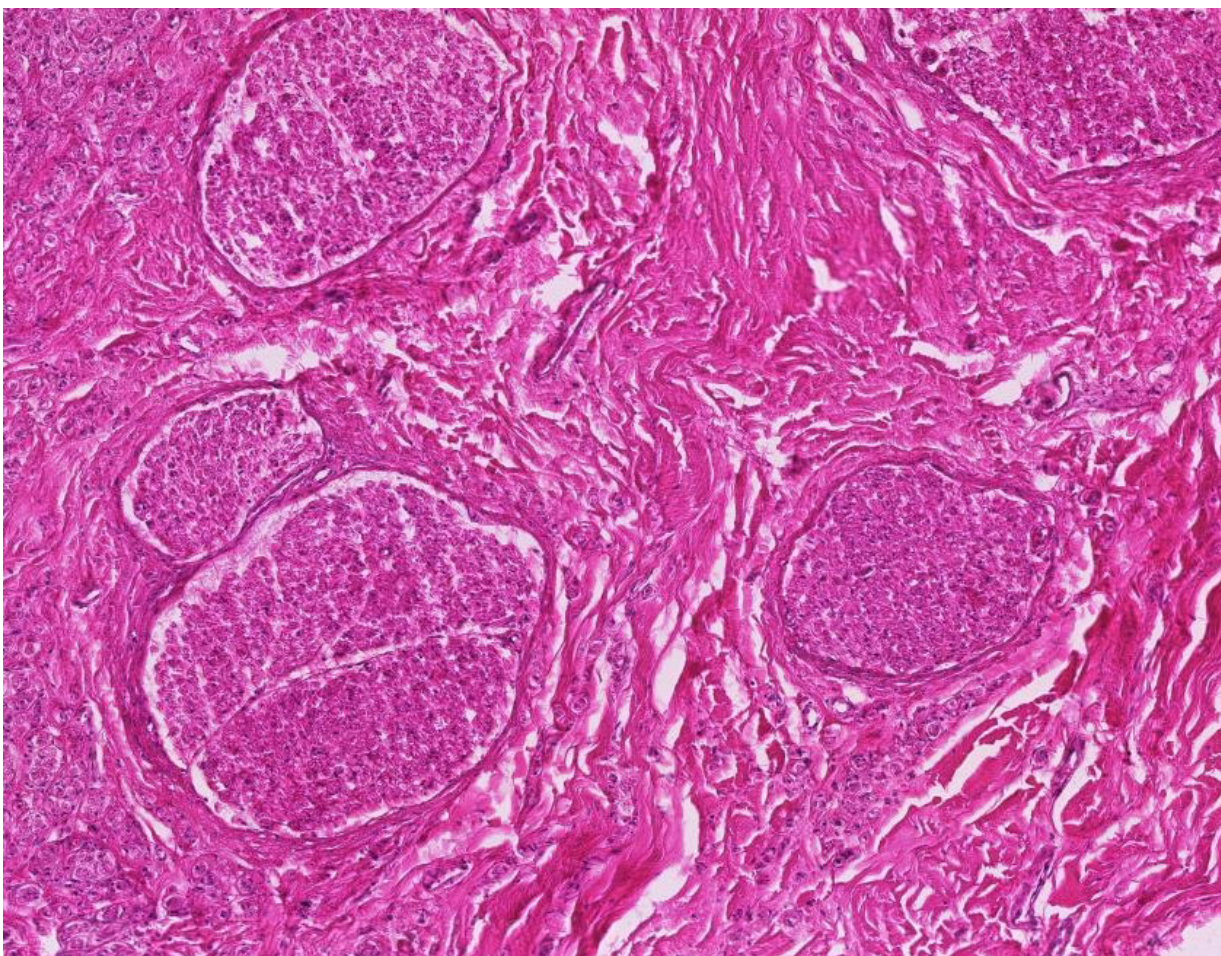
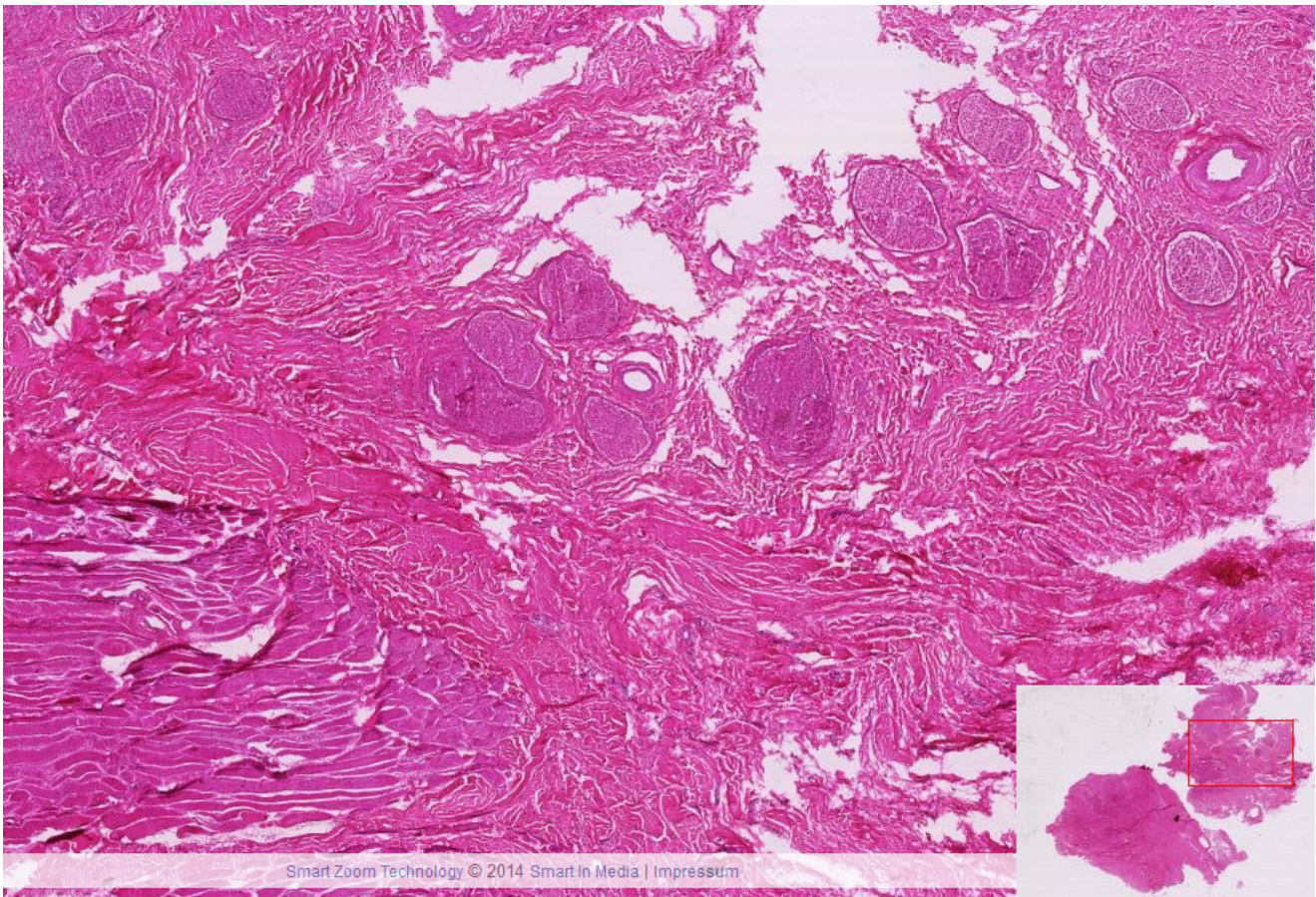
V-2 Granulomatöse Parotitis(Heerfordt Syndrom)



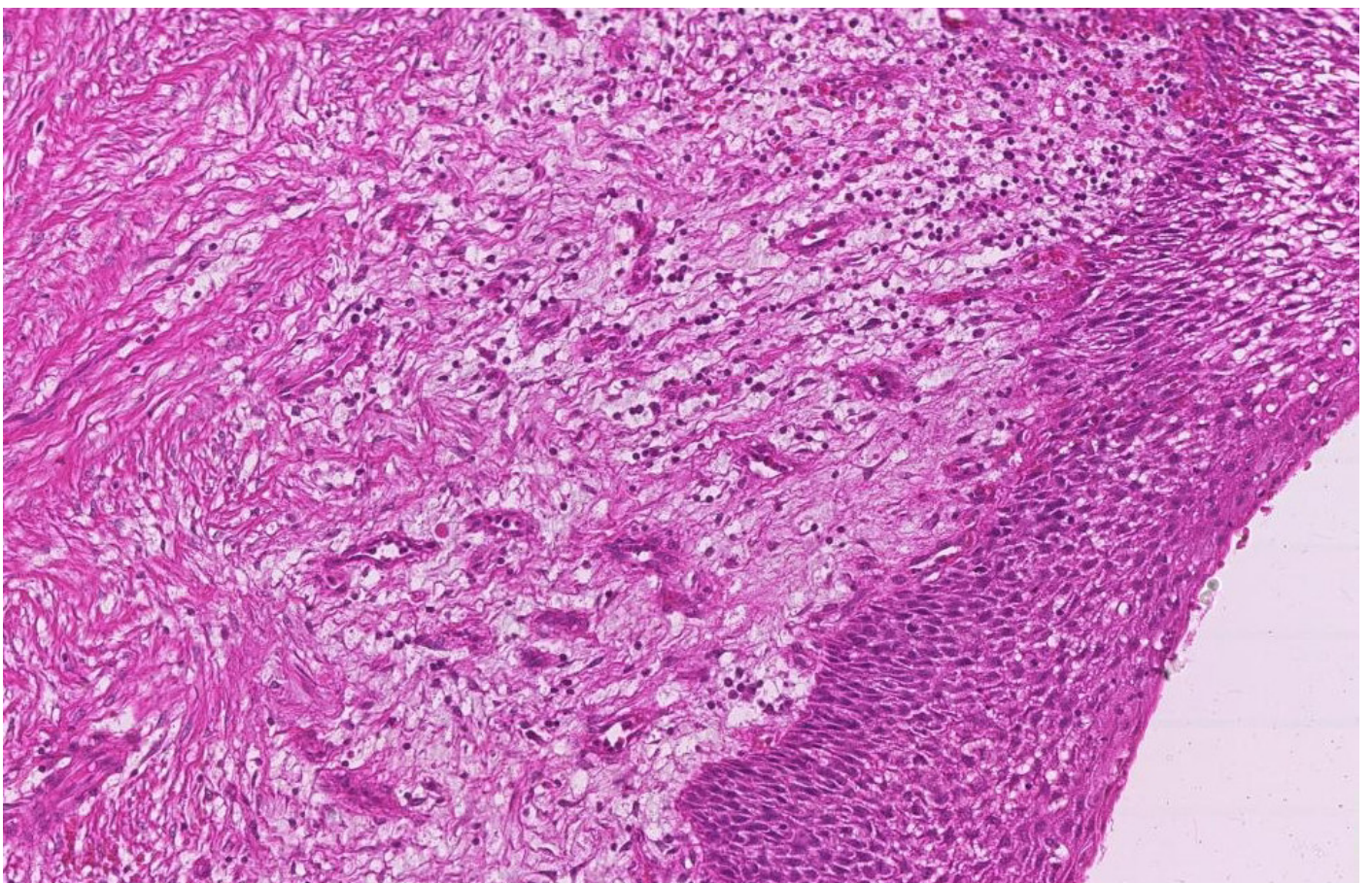
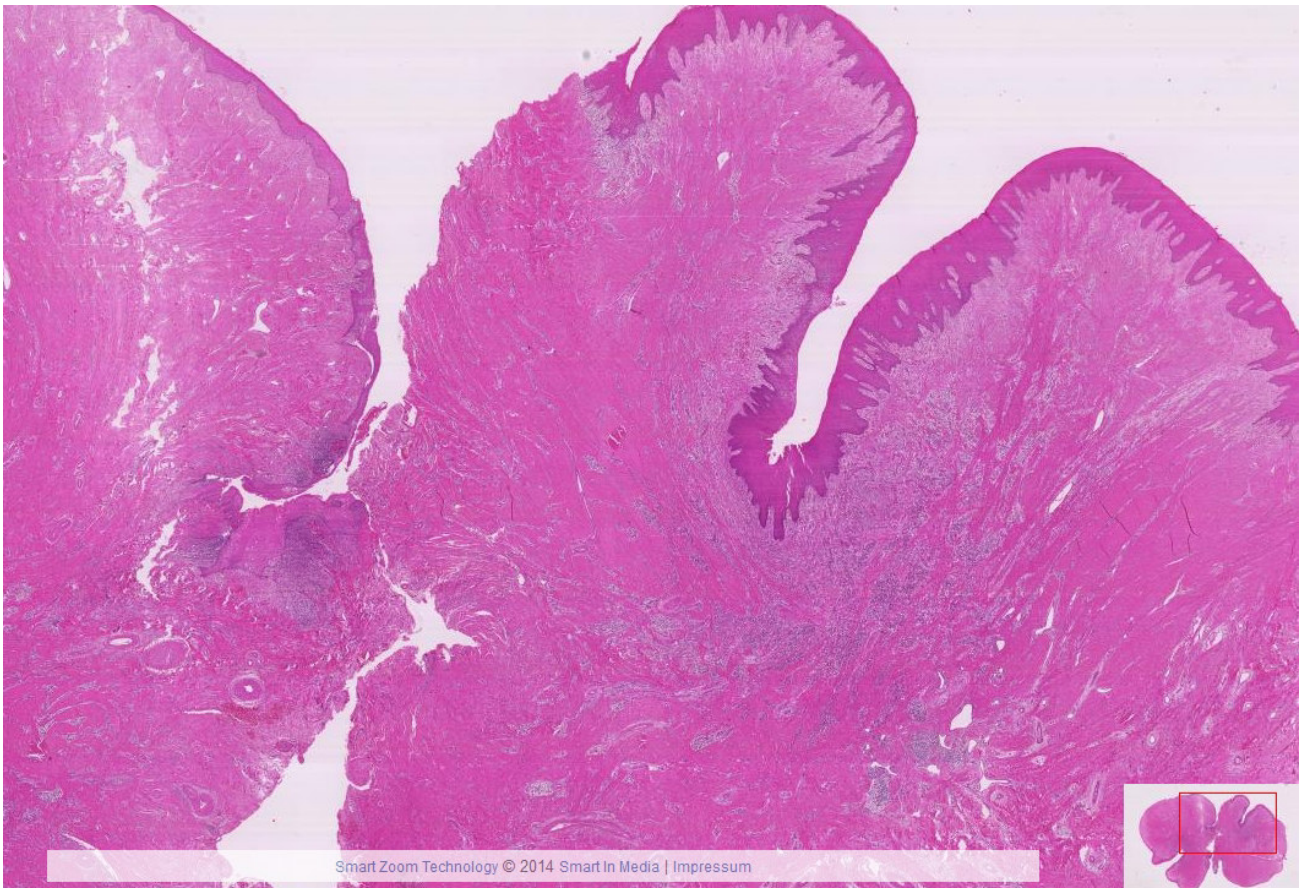
V-3 Fremdkörpergranulom(Haut)



V-4 Narbenneurom(Weichgewebe)



V-5 Reizfibrom(Mundhöhle)



V-6 Haarzunge

